



# Osteotomy: high tibial (valgus) osteotomy and distal femoral (varus) osteotomy

---

**This leaflet outlines osteotomy surgery for knee problems caused by osteoarthritis. If you have any queries after reading it please discuss with your physiotherapist or contact the physiotherapy department on 0118 322 7812 Monday to Friday 8am to 4pm.**

---

## Osteoarthritis and the knee

Osteoarthritis (“wear and tear”) often affects one side of the knee joint more than the other – a *unicompartmental* arthritis – and can result in knee pain and deformity. When non-operative treatments – painkillers, anti-inflammatory drugs, Chondroitin / Glucosamine, physiotherapy, exercise programmes and weight loss – have not been successful in controlling the pain, a major surgical procedure such as a joint replacement or an osteotomy is usually recommended.

## How does an osteotomy work?

When there is unicompartmental arthritis realignment, osteotomy can ‘offload’ the affected compartment of the knee and move the body weight onto the healthier side of the knee. This procedure will ‘preserve’ the joint surface, maintain the bone and avoid the restrictions that accompany a knee replacement. However, it does not rule out any future surgery, such as partial or total knee replacement. It is often thought of as ‘buying time’ for the knee.

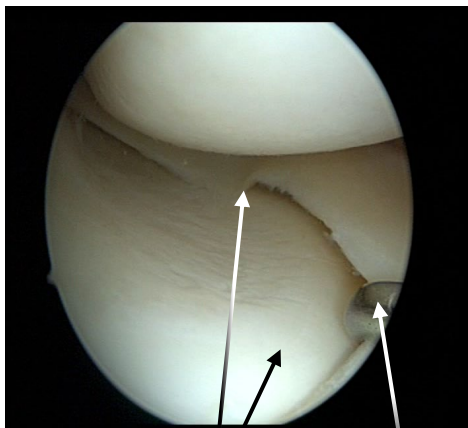
Total knee replacement (TKR) and unicompartmental knee replacement (UKR) are frequently performed operations. In 2019 there were 103,617 total knee replacement operations done in England and Wales (10% of which were unicompartmental knee replacements). These were mostly successful, with approximately 80% of patients being happy with their result following total knee replacement (UK National Joint Registry). However, a joint replacement will have a ‘lifespan’, which will be **reduced** in younger, more active patients. In addition, post-operative limitations to activities such as running and heavy manual working may not suit the more active patient. Total joint replacement also involves the removal of some of the healthy bone and dividing at least one of the major knee ligaments. Revision joint surgery is possible for the ‘failed’ joint replacement but each time this takes place the outcome is less satisfactory, both in terms of function and complications.

The following pages will cover the reasons for your current symptoms, the potential benefits of having an osteotomy, the risks involved and what to expect after the procedure.

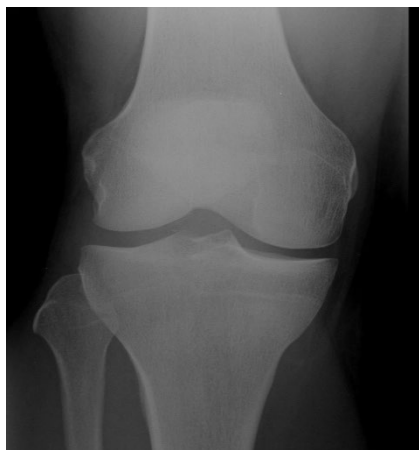## Knee anatomy and the problem

The knee joint is formed by the lower end of the thigh bone (the femoral condyles) and the upper surface of the shin bone (the tibial plateau). The joint is divided into two halves or

compartments – the medial (inner) and lateral (outer) compartments. A smooth substance - articular cartilage - normally covers the surface of these bones and minimises friction and weight transmission to the underlying bone.

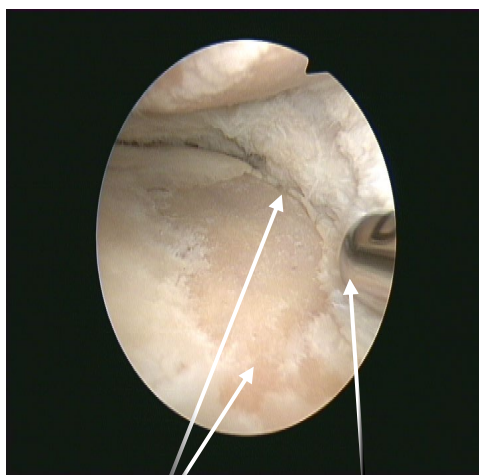


Normal articular cartilage and meniscus



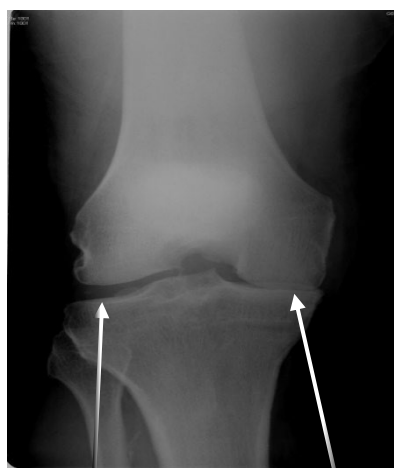Normal X-ray

Osteoarthritis (OA) is the direct consequence of this articular cartilage thinning and eventually exposing the underlying bone. OA is strongly associated with age and genetic (hereditary) factors but could also be the result of previous injury (fracture or other), previous surgery (meniscectomy), previous infection or coexisting inflammatory joint conditions.



Exposed bone  
("Bone on bone")

Torn resected meniscus



'Healthy'  
joint space

Bone on bone

When standing or walking ('weight bearing'), the force is transmitted from the centre of the ankle to the centre of the hip (femoral head). This 'weight bearing line' (mechanical axis / alignment) will pass through the knee – usually through the centre or just on the inner side of the midline. However not everyone is 'made the same' and there is great variability in what we may consider to be normal for each individual.

When the articular cartilage and bone wears away from the medial or lateral compartment – causing bowleg (**varus**) or knock knee (**valgus**) deformities – it will result in a change of this mechanical axis. This in turn will lead to more of the body weight being transmitted through that

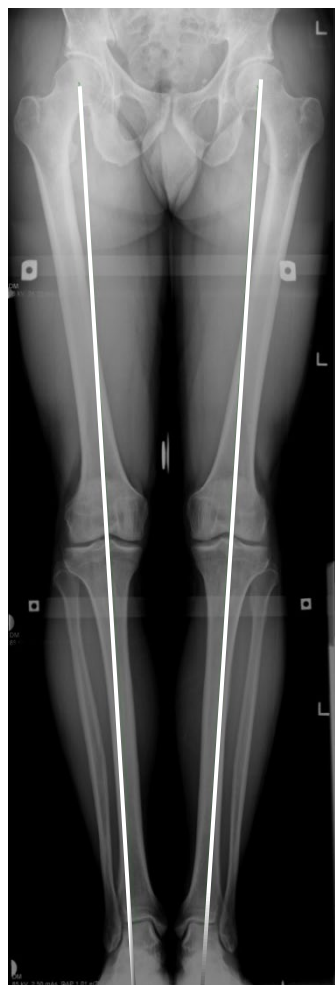Compassionate

Aspirational

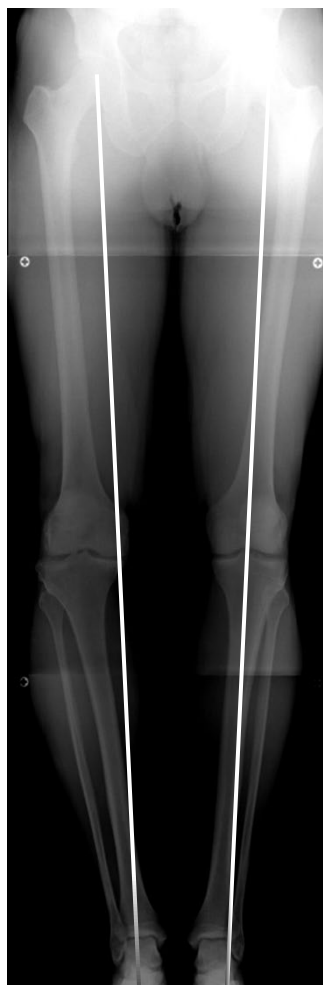Resourceful

Excellent

affected compartment, overloading the underlying bone causing changes in the structure of the bone and **pain**.



'Normal' alignment



Varus alignment

This malalignment will (or should) be corrected when performing a total or partial joint replacement but 'joint preserving' procedures such as osteotomy are usually a preferable alternative in younger, more active patients, but can be done at any age.

### **Osteotomy – general information**

There is no evidence that leaving an arthritic knee without surgery puts it at any particular risk but it is likely the pain and deformity may worsen with time.

An osteotomy does involve cutting – and then fixing – the bone which implies that the 'fracture' will need to heal. This healing is **significantly reduced** in patients who smoke and this procedure is therefore **not** recommended for patients who are smokers.

Osteoarthritis is sometimes the long term consequence of previous injury involving the major knee ligaments. The ligaments stabilise the knee and therefore arthritis can sometimes be associated with instability or giving way.

Osteotomy can in some cases – by changing the shape of the upper surface of the shin bone (tibia) – improve the stability of the knee as well as offloading an arthritic compartment.

Arthroscopy (keyhole surgery) is still sometimes used to fully assess the extent of the arthritis in the knee joint. This information will help the surgeon decide which major procedure is appropriate.

The aim of an osteotomy is to reduce pain and improve function. It may not produce complete relief of pain but it **should** significantly improve the pains from that compartment of the knee.

For the best long term results it is suggested that the deformity is **overcorrected** – resulting in a mild knock knee (valgus) appearance. Some patients may find this unacceptable.

### **Pre-operative exercise(s)**

Besides the general health and wellbeing aspects of fitness, patients who already have good muscular strength and control will find the post-operative recovery easier. Exercises that are recommended are those 'lower impact' activities, such as cycling, rowing and the cross trainer.

### **Anaesthesia / pain management**

Having an osteotomy will usually require a general anaesthetic, i.e. 'completely asleep'. This will be discussed on the morning of your surgery by the anaesthetist as will appropriate measures to reduce any post-operative pain. At the time of your anaesthetic, intravenous antibiotics will also be given to reduce the risk of infection.

### **Surgical wound**

Following general anaesthesia, a tight inflatable band (tourniquet) is applied to the upper thigh to restrict the bleeding during the procedure. The surgeon will make a longitudinal incision (cut) at the side of the tibia or femur, which will later be closed with stitches or clips. A drain may be inserted into the wound to collect any blood that may accumulate. This is removed the day after your surgery. The stitches or clips will need to be removed 10-14 days after your operation and can be done at your local GP practice. You will be able to shower while the stitches or clips are still in place.

### **When should an osteotomy not be done?**

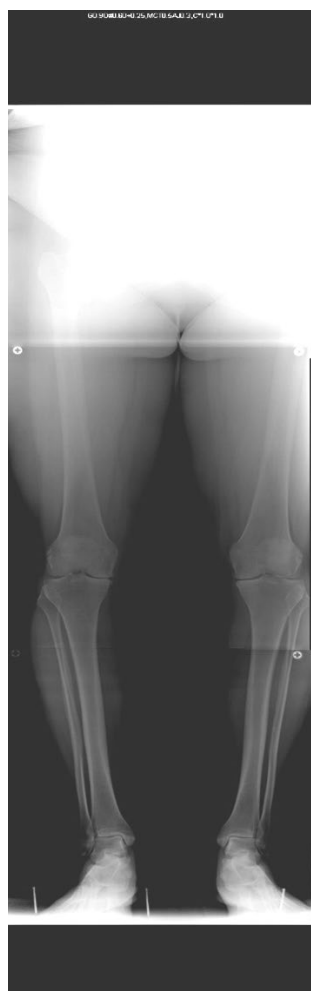- If you smoke.
- If there are signs of arthritis or previous removal of cartilage from the other joint compartment.
- If you have inflammatory joint disease.
- If you have significant patello-femoral / anterior knee pains.
- If you have stiff knees.
- If your knees have 'significant' deformity.

## How is an osteotomy done?

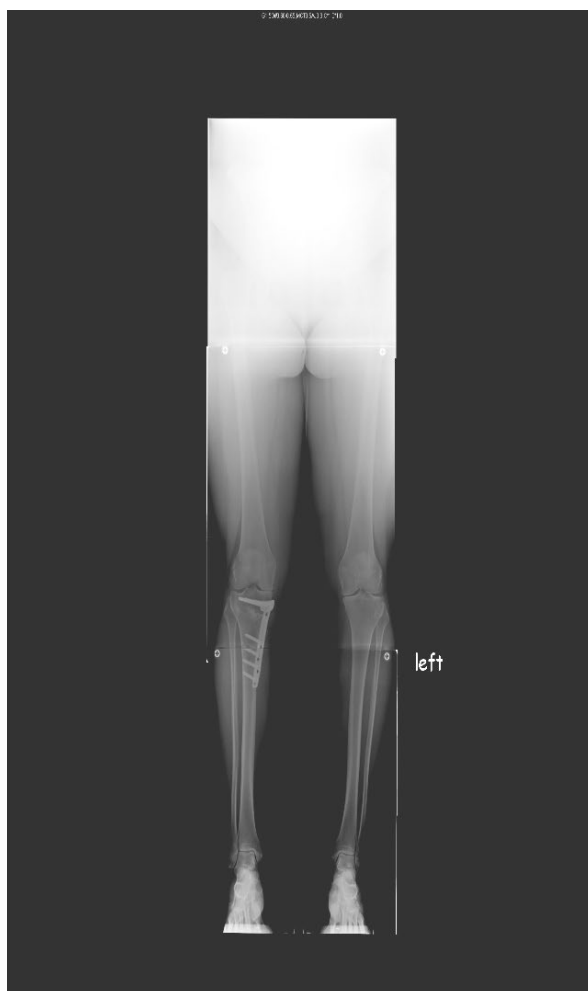
There are two main techniques of realigning the knee joint. Both involve cutting the bone above or below the knee with a saw using X-ray guidance. The 'fracture' is then stabilised with a plate and screws. The pre-operative planning of the osteotomy is the key to the success of this procedure. This is done with the aid of computer software and uses measurements taken from the 'long leg' X-ray you will have had done. This will help determine which type of osteotomy you will require and how large a correction will be necessary at the time of surgery.

**Closing wedge osteotomy:** This involves two bone cuts to remove a wedge of bone either from the tibia (shin bone) for bowleg deformity or femur (thigh bone) for knock-knee deformity. Subsequently the 'fracture gap' is brought together and held in position with staples or a plate and screws.

**Opening wedge osteotomy:** After the bone cut is made, the two sides of the 'fracture' are separated by a pre-determined angle to form a wedge-shaped opening. The osteotomy is then stabilised with a plate and screws. Small corrections do not require bone grafting but larger corrections may be filled with bone graft from the patient (usually from the hip), sterilised bone chips or a synthetic wedge of 'calcium based' material.



Varus deformity



After osteotomy

Compassionate

Aspirational

Resourceful

Excellent

## Risks and potential complications of an osteotomy

- **Post-operative bleeding:** A suction drain is sometimes used to collect any bleeding but some bruising will still occur. If a collection of blood (haematoma) results, it may need to be drained.
- **Altered wound healing / sensation:** Most heal well but the wound may become red, thickened and painful (keloid) – more common in people of Afro-Caribbean descent. Damage to the small skin nerves can result in some temporary or permanent alteration of sensation to the skin on the front of the knee.
- **Wound infection:** Despite the routine use of antibiotics, infections may still occur. Another operation may be required to wash out the infected wound and – if involved – the metalwork may need to be removed and replaced at a later stage.
- **Removal of the metalwork:** If the plate becomes so that you can feel it or if it causes discomfort, it may need to be removed when the osteotomy has healed. This may also be recommended, even if not causing symptoms.

## Risks in approximately 1-5 in 100 patients

- **Blood clots (Deep Vein Thrombosis / Pulmonary Embolism):** Following all major lower limb surgery there is a risk of forming a blood clot in the calf (DVT). These can occasionally break off and move through the blood stream to the lungs (pulmonary embolus). A large pulmonary embolism may be fatal (3 in 1000 cases of total knee replacement). You will be given treatments to reduce this risk – calf compression device, early ankle movements / mobilisation. “Blood thinning agents” are not given due to the high risk of excessive bruising / bleeding.
- **Delayed healing / ‘non-union’ of the bones:** Sometimes, the two bone edges do not unite (heal together) as planned – known as a non-union. Smoking significantly impairs bone healing and this procedure is not therefore recommended for those who smoke. This usually requires a further operation.
- **Intra articular fracture:** A fracture into the knee joint may occur that will require additional fixation.

## Risks in approximately 1-5 in 1000 patients

- **Compartment syndrome:** Post-operative bleeding into the calf muscles may cause an increase in pressure and significant pain. This requires an emergency procedure to release the muscle compartments under pressure. The wounds are usually left open and may require skin grafting at a later stage.
- **Damage to the major nerves around the knee:** Very rarely, the larger nerves around the knee can be involved resulting in temporary or permanent weakness and/or altered sensation.
- **Damage to the blood vessels behind the knee:** This can lead to loss of circulation to the leg and foot. If this happens you will need immediate surgery to restore the blood flow and could result in amputation (very rare).

## After your operation

You will have no external splints, braces or plaster on your leg after the surgery. The stability will be provided by the rigid internal fixation of the plate and screws. You will be encouraged to regain a full range of extension (straightening) and flexion (bending) as soon as possible after the operation and to begin some strengthening exercises when comfortable.

Your physiotherapist will show you some general exercises to perform to aid your early recovery and mobility and may give you a booklet to take home with you.

If you have had high tibial osteotomy, you will be able to weight-bear as comfort allows on the day following surgery and your physiotherapist will also help you with this.

If you have had a distal femoral osteotomy, you will be touch toe weight bearing for the first 6 weeks.

Most patients can go home on the day following surgery as long as:

- The pain is under control and a plan has been established for reducing analgesia at home.
- You are able to get in and out of bed.
- You can walk confidently using your crutches to access the bathroom.

Uneventful recovery from an osteotomy may take 4 to 6 months. As the osteotomy heals you will feel less pain and more confident when walking. You will have an X-ray at 6 weeks and 3 months to assess the bone healing. When you are safe putting full weight through the leg several types of balance exercises can be chosen to further control and stabilise the knee.

## Crutches / Mobilisation

Typically, you will need crutches for 4 to 6 weeks but will be full weight bearing before 6 weeks if all goes to plan (for high tibial osteotomy patients). For distal femoral osteotomy patients you will be touch toe weight bearing for 6 weeks with gradual increase in weight bearing after this if all goes well.

## Eating and drinking

Following your operation, you may feel nauseous – a common symptom following surgery and a frequent side effect of pain-relieving drugs. If severe, medication can be given to help with this.

## Driving

Usually not for 6 weeks following this major procedure but this will depend on comfort and confidence when walking / moving. Distal femoral osteotomy patients can return to driving at 6-10 weeks post operatively, once they have discontinued using crutches and are able to perform an emergency stop safely.

## Sex

As able when comfortable, although kneeling may be difficult for the first few weeks.

## Sports

Research indicates that only a few individuals are able to return to their previous high level of sporting activity following an osteotomy – whether or not an ACL reconstruction is done at the

same time or not. However, most are able to return to leisure sports activities such as walking, hiking, cycling, swimming, tennis. Contact sports and distance running are not recommended, although the patient should ultimately be guided by how they feel about their own knee.

As long as the osteotomy heals and there are no other complications, swimming and gentle cycling / rowing may be commenced at about 3 months. There are no restrictions but it may be 6 to 9 months before vigorous sporting activity can be resumed.

## What are the results?

Osteotomy has been performed for arthritis for centuries and many surgeons have reported their results. But the variety of techniques used, different methods of recording results and small numbers involved in each study have meant that there is still no consensus regarding certain aspects of this surgery. The question of 'what is success' has not been answered and 'failure' is commonly accepted as the time at which a joint replacement is finally done. Little comment has been made on the quality of those 'added years' before joint replacement.

However, two factors are consistently recognised as being very important:

- Appropriate **patient selection**.
- Quality **surgical technique**.

### **Patient selection: it is generally acknowledged that the best results are seen in:**

- Patients under 60 years.
- Smaller deformity, i.e. relatively early in the arthritic process.
- Unicompartmental disease (i.e. only one side of the knee affected).
- Stable ligaments.
- A good pre-operative range of motion (greater than 90°).
- No inflammatory joint disease.
- No significant patello-femoral (anterior knee) pain.

**Surgical technique:** the introduction of planning software has improved the accuracy of the operative correction and this may still be improved further with the introduction of 'computer aided' surgery.

Poorer longer term survival is seen with:

- Under-correction of the deformity.
- Penetration of the joint / intra articular (into the joint) fracture.

The success of the operation varies between reports but approximately 90% of patients will have improvement that definitely last 5 years. After 5 years, the benefit will depend directly on the accuracy of the post-operative correction, which is determined by further long leg X-rays. If a sufficient correction was achieved at osteotomy and symptoms (pain) increase with time then a joint replacement will be the only surgical alternative.

Results range from 90% (for high tibial osteotomy) and 92.3% (for distal femoral osteotomy) benefit at 10 years. Under-correction was associated with higher revision rates (need further surgery) whereas neutral or overcorrection has results which rival the survival of joint replacements.



## References

1. Heidari KS, Heckmann N, Pannell WC, Hill JR, McKnight BM, Vangsness CT, Hatch GFR. Distal Femoral Osteotomy Survivorship: A Population-based Study. *Orthop J Sports Med.* 2017 Jul 31;5(7 suppl6):2325967117S00293. doi: 10.1177/2325967117S00293. PMID: PMC5542335.
2. Pannell WC, Heidari KS, Mayer EN, Zimmerman K, Heckmann N, McKnight B, Hill JR, Vangsness CT, Hatch GF, Weber AE. High Tibial Osteotomy Survivorship: A Population-Based Study. *Orthop J Sports Med.* 2019 Dec 30;7(12):2325967119890693. doi: 10.1177/2325967119890693. PMID: 31909056; PMID: PMC6937536.

## Useful numbers and contacts

Orthopaedic Outpatients Clinical Admin Team (CAT 5) 0118 322 7415

or email: [rbb-tr.cat5@nhs.net](mailto:rbb-tr.cat5@nhs.net)

Physiotherapy Outpatients 0118 322 7812

Visit the Trust website at [www.royalberkshire.nhs.uk](http://www.royalberkshire.nhs.uk)

**Please ask if you need this information in another language or format.**

Debbie Burden (Orthopaedic Specialist Physiotherapist) / Sean O'Leary FRCS (Trauma & Orthopaedic Surgeon) / Sam Nahas MBBS, BSC, Med, FHEA, FRCS (Trauma & Orthopaedic Surgeon)

Reviewed: November 2024

Next review due: November 2026