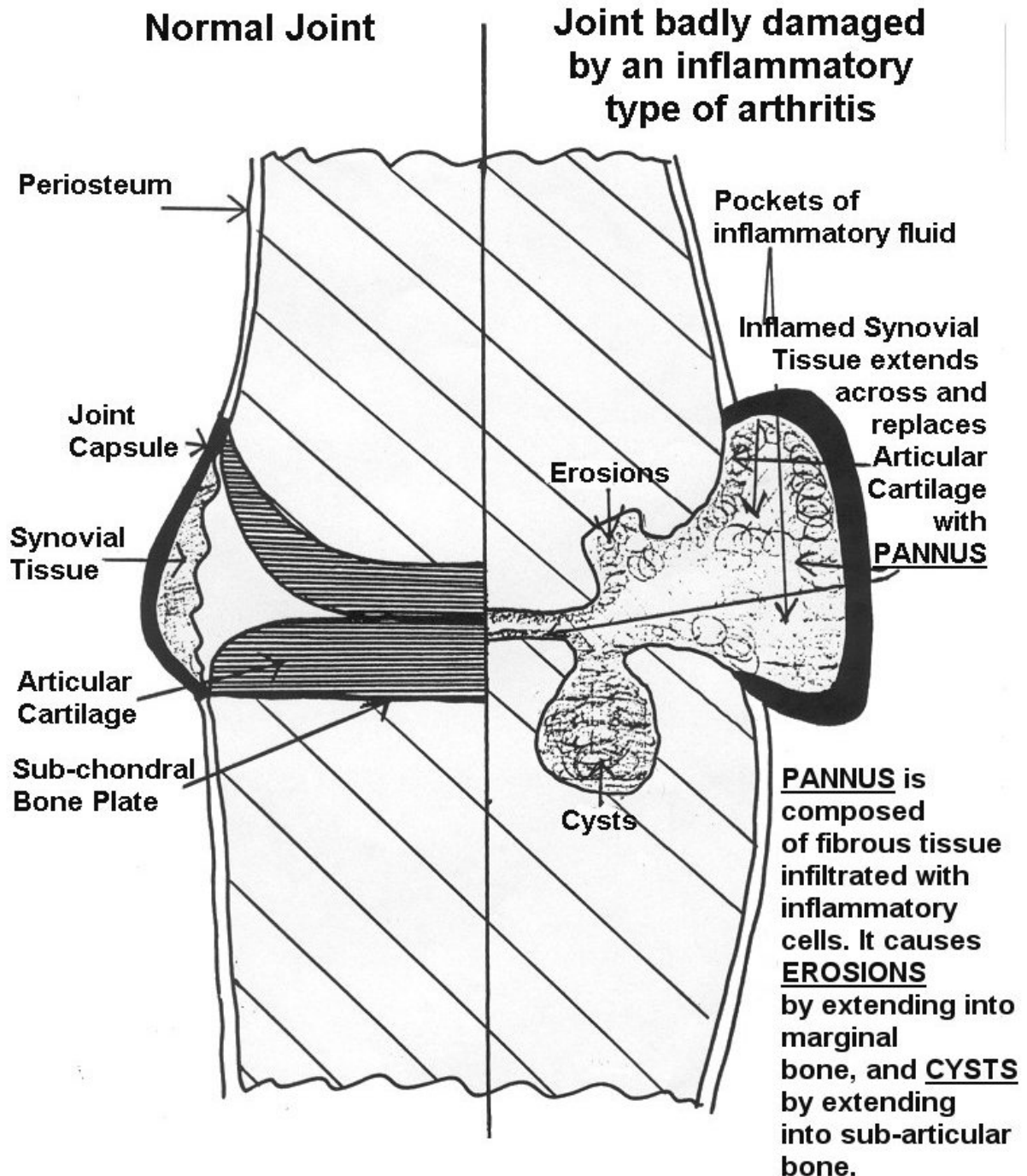


Diagram of a typical synovial joint



For further information about the Trust, visit our website www.royalberkshire.nhs.uk

West Berkshire Rheumatology Unit

Reviewed: January 2025

Next review due: January 2027